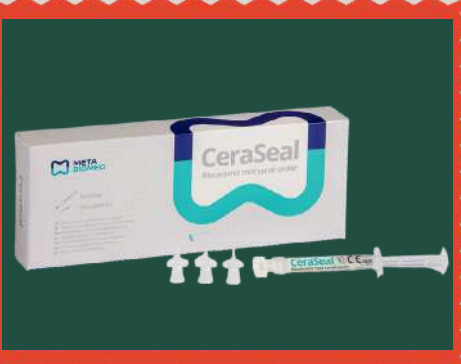
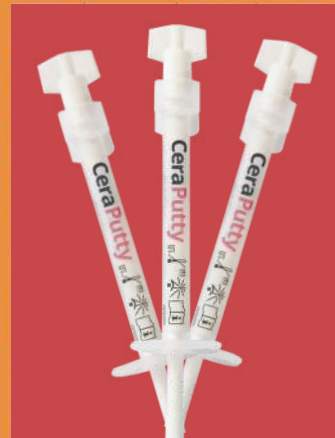
Flossing

5TH ISSUE DECEMBER 2024



CeraPutty
Case Report
By Prof. Talal
Al-Nahlawi



Meta Biomed
Summit
Symposium
In Vietnam

Explore
the World
with Meta
Biomed

CeraSeal
Case
Review
By Dr. Mostafa
Anwar



CeraSeal
Clinical Case
By Dr. Filippo
Cardinali



Upcoming
Events
in Q1

META BIOMED
ONEDREAM
Established 1999
META **ONE** BIOMED
TEAM

META BIOMED SUMMIT SYMPOSIUM IN VIETNAM



NOVEMBER 24TH, 2024



FOUR KEY OPINION LEADERS FROM AROUND THE WORLD GATHERED!

META BIOMED SUMMIT SYMPOSIUM

On November 24th, the Meta Biomed Summit Symposium 2024 held in Ho Chi Minh, Vietnam, became a significant dental event in the year 2024. The symposium featured four renowned international speakers: Dr. Filippo Cardinali from Italy, Dr. Talal Al-Nahlawi from Syria, Dr. Jenner Argueta from Guatemala, and Dr. Mostafa Anwar from Egypt. Nearly 300 local dentists and students attended, adding to the passionate atmosphere of the event. The attendees had the opportunity to hear from these prominent speakers on the clinical potential of CeraSeal and CeraPutty, with a focus on their versatility and clinical applications. The speakers offered a unified vision for a new dental treatment paradigm using these products.



Dr. Jenner Argueta introduced scientifically based clinical techniques for saving teeth in complex situations. He shared many cases where he successfully saved teeth that were at risk of being lost by using CeraSeal and CeraPutty. He demonstrated how these products could be used effectively in complex clinical scenarios, offering the audience valuable insights into their application.

Dr. Talal Al-Nahlawi showcased various clinical cases where CeraSeal and CeraPutty were applied in different situations, such as vital pulp therapy, open apical treatment, root perforation repair, and micro-endodontic surgery. He emphasized the importance of understanding and correctly applying CeraSeal for optimal treatment outcomes. His lecture provided clear guidance on which cases are best suited for CeraSeal.



Dr. Mostafa Anwar highlighted the role of CeraSeal in achieving high-quality 3D obturation. He shared multiple clinical cases demonstrating the effectiveness of CeraSeal in complex root canal anatomies, and how CeraPutty was used in challenging situations like root perforation and open apex. His presentation proved that CeraSeal and CeraPutty play crucial roles in restoring even the most difficult cases.

Dr. Filippo Cardinali detailed the properties and advantages of Cold Hydraulic Condensation using CeraSeal, based on his extended clinical experience. He discussed his clinical results and shared statistical data, emphasizing the importance of following a precise protocol to ensure patient-centered outcomes. He also offered guidance on optimizing the use of CeraSeal to achieve long-term treatment success.

META BIOMED VINA FACOTRY TOUR

The following day, the four speakers were invited by Meta Biomed VINA to visit the factory where Gutta Percha Points and Paper Points are produced. Meta VINA factory is the largest hand-rolling GP, PP production base in the world, and it proudly boasts the most advanced equipment and systems for producing these products. They were able to witness firsthand how GP and PP are made and even took part in the production process alongside skilled workers in the factory. All of them expressed how invaluable it was to see the actual production process of products they had been using in clinical practice for years. This experience left a lasting impression on everyone involved. Despite the challenges faced by the factory during the COVID-19 pandemic a few years ago, Meta Biomed VINA has now fully recovered and is ready to provide high-quality products to meet the needs of the market. The factory tour helped the four esteemed speakers appreciate the dedication to quality and innovation at Meta Biomed, reinforcing the trust they already had in the brand.



Dr.Filippo Cardinali in Poland

Meta Biomed Europe successfully supported a seminar in collaboration with its Polish partner, Poldent. Held on October 5, 2024, in Warsaw, Poland, the event featured Dr. Filippo Cardinali, who delivered three engaging lectures and hands-on workshops. Dr. Cardinali provided participants with valuable insights and practical experience in endodontics. This collaboration reflects Meta Biomed Europe's commitment to enhancing education and fostering progress in the field of endodontics. We look forward to an even stronger partnership between Meta Biomed Europe and Poldent, and we wish for their continued success. 📧



Live Webinar with CAPP

Meta Biomed is pleased to share the successful completion of the live webinar, "3D Bioceramic Obturation: Scientific Evidence and Clinical Scenarios," held on October 30, 2024. Following the success of the May and September sessions, this third webinar once again drew the interest of tons of participants. Led by Dr. Mostafa from Egypt, the session focused on the scientific evidence and clinical advantages of CeraSeal Bioceramic sealer, providing attendees with practical insights to improve root canal treatment outcomes. We extend our heartfelt gratitude to all participants for their enthusiasm and continued support. Meta Biomed remains committed to delivering valuable and engaging programs. Stay connected with Meta Biomed on social media for updates on upcoming events! 📧

Supported by **META BIOMED** Organised by **CAPP**

LIVE WEBINAR

1 CE CREDIT

30 OCT
19:00 UAE (GST)
18:00 KSA
17:00 CEST

Dr Mostafa Anwar, Egypt
3D bioceramic obturation:
Scientific evidence and clinical scenarios

www.cappmea.com/webinars

Meta Biomed Bioceramics Symposium with Alexdent

On October 31, 2024, 'Meta Biomed Bioceramics Symposium' was successfully held in Cairo, Egypt, in collaboration with our Egyptian partner, ALEXDENT. The session was led by Dr. Mostafa, focusing exclusively on bioceramics, CeraSeal & CeraPutty. This session provided attendees with advanced knowledge of bioceramics, while Dr. Mostafa shared his valuable practical skills for its application. Meta Biomed and ALEXDENT plan to host another session in the first half of next year and look forward to the continued interest and participation of Egypt's passionate doctors. 📧

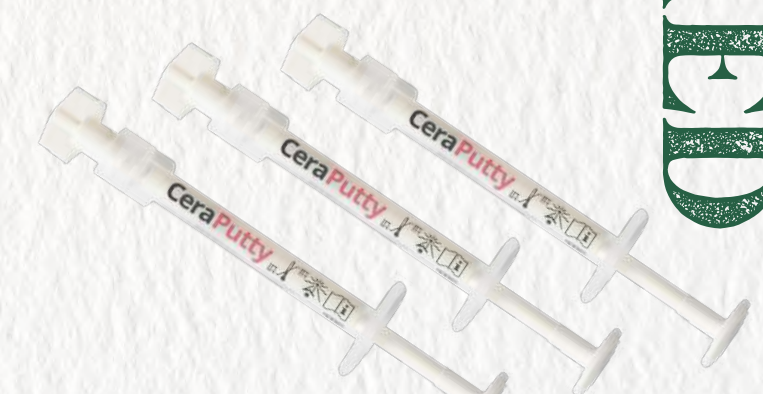

APDIA Conference & Taiwan World Dental Show

Meta Biomed's key Taiwanese partner, UNIGLIFE, participated in the APDIA Conference & Taiwan World Dental Show in November. For this event, they invited Dr. Yu-Hua Kuo, the second-place winner of the Saving the Natural Tooth Contest 2022, as a keynote speaker. Dr. Kuo's lecture, titled "Hydraulic Condensation with CeraSeal: Would We Use Single Cone Obturation with CeraSeal?" provided valuable clinical cases and practical tips on CeraSeal. More than 80% of the approximately 70 attendees expressed complete satisfaction with the session. We look forward to continuous collaborations between UNIGLIFE and Meta Biomed in Taiwan! 📧

Indonesia 4.5 in Indonesia

The 1st Style Italiano Endodontics Congress in South East Asia, "Brings the World to INDONESIA 4.5", was successfully held from November 20 to 22, 2024, in Jakarta, Indonesia. With over 450 attendees, the event featured dynamic lectures and valuable insights into advanced endodontics. Especially, Dr. Filippo Cardinali delivered an outstanding lecture titled "Obturation with Bioceramic Sealer for Patient-Centered Endodontic Outcomes: Understanding Materials and Protocol", where he highlighted the benefits of CeraSeal and its clinical applications. Meta Biomed sincerely thanks all participants for their active engagement and enthusiasm, making this event a great success. 📧





Prof-Dr. Talal Al-Nahlawi

Associate Professor,
Department of Operative Dentistry
and Endodontics,
Syrian Private University
& Damascus University

Case Report

Micro-surgery of Persisting Apical Pathosis with **CeraPutty** Retrograde Obturation; a 3.5 Years Recall

Case Report

Micro-surgery of Persisting Apical Pathosis with **CeraPutty** Retrograde Obturation; a 3.5 Years Recall

Courtesy of Prof-Dr. Talal Al-Nahlawi

Introduction

Case report

The good compatibility as well as sealing ability of Bioceramics material allowed it to be used as a retrograde material during apical surgery with high success rate (1).

30 years old female patient was referred complaining from repeated swelling in the anterior upper teeth area after 2 previous apical surgeries.

Clinical examination revealed palpation pain over apex area of upper right lateral incisor #12, with fixed prosthesis, and the X-Ray examination showed persisting apical lesion with over-extended obturation material due to previous failing apicoectomies. *Figure 1.*

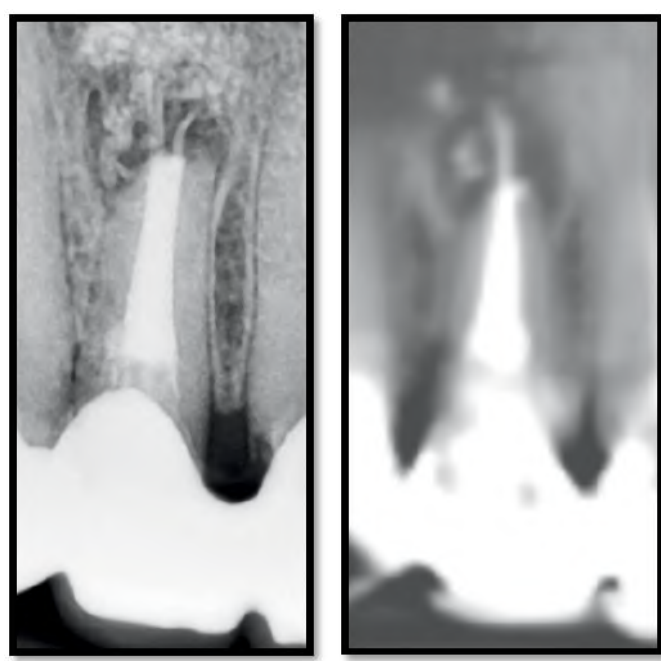


Figure 1 Pre-operative X-Ray and CBCT image showing persisting apical lesion after two apicoectomies.

A diagnosis of symptomatic apical periodontitis was confirmed, and the treatment plan was to perform micro-surgical apicoectomy to correct previous mistakes and to seal source of infection using retrograde obturation.

After profound anesthesia, incision, and flap retraction, the peri-apical lesion as well as the over-extended obturation materials were removed. *Figure 2*

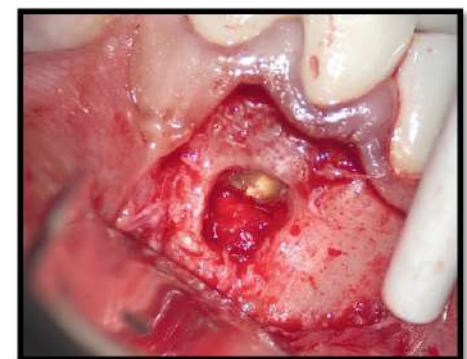


Figure 2 Bone cavity after lesion removal and tooth apex exposure

After retrograde preparation with ultrasonic tips, along with bleeding control and cavity dryness, *Figure 3,*

the retrograde cavity was obturated with LID technique(2) using **CeraSeal** bioceramic sealer, *Figure 4,*

covered by **CeraPutty** bioceramics putty material, *Figure 5,* from **Meta Biomed** to completely obturate the retrograde cavity, *Figure 6.*

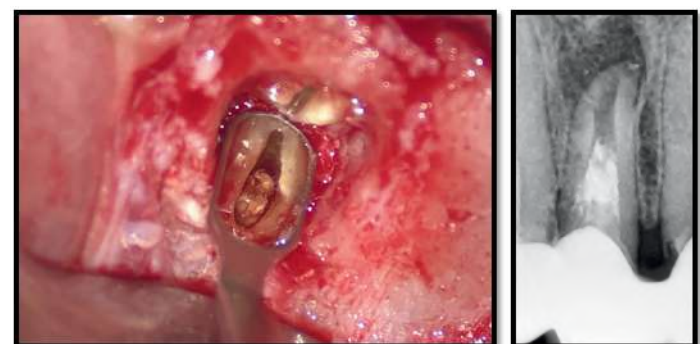


Figure 3 Retrograde cavity preparation clinically and on X-Ray.

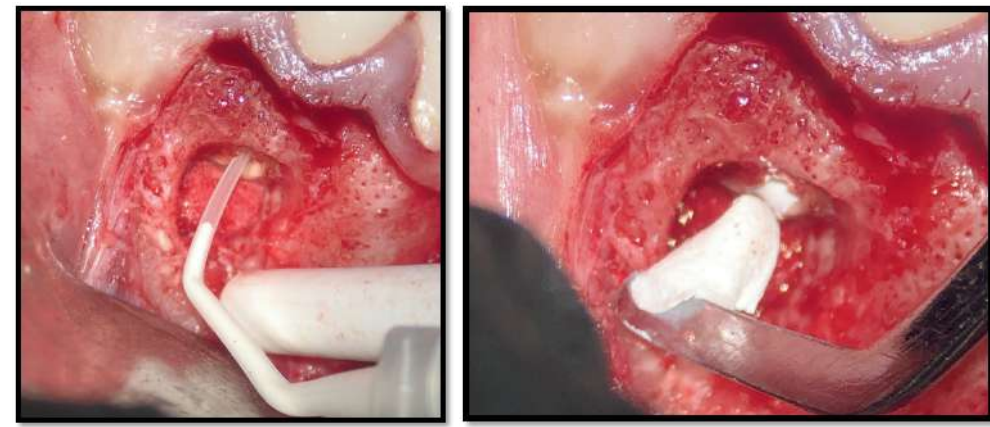


Figure 4 Application of **CeraSeal** Sealer (**Meta Biomed**)

Figure 5 The application of **CeraPutty** (**Meta Biomed**) to completely obturate the retrograde cavity

Case Report

Micro-surgery of Persisting Apical Pathosis with **CeraPutty** Retrograde Obturation; a 3.5 Years Recall

Courtesy of Prof-Dr. Talal Al-Nahlawi

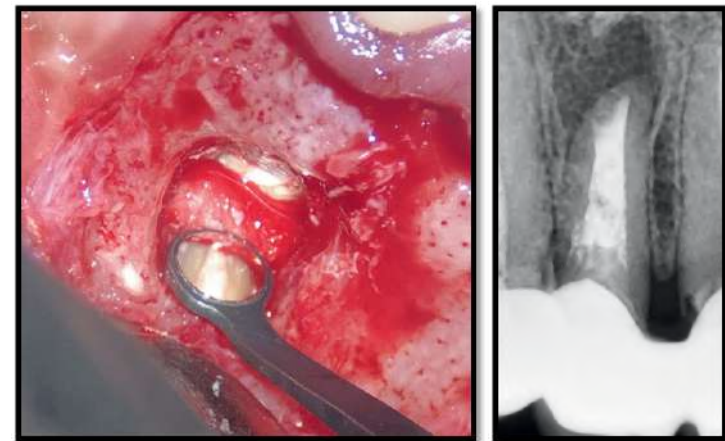


Figure 6 Hermetic seal provided by **CeraPutty** and **CeraSeal** Bioceramics materials combination confirmed clinically and radiographically.

The 3.5 years recall periapical X-Ray revealed complete healing and formation of periodontal ligament PDL, **Figure 7**.

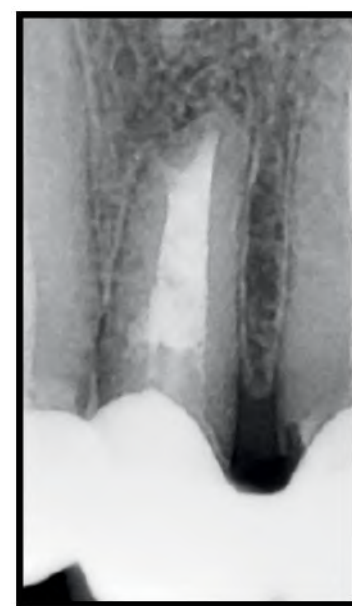


Figure 7 3.5 years recall X-Ray examination showing complete healing and bone formation over the **CeraPutty**.

Conclusion

The hermetic seal obtained by the combination between **CeraSeal** and **CeraPutty** was able to fill the retrograde cavity sufficiently to prevent the recurrence of the surgery again and the great biocompatibility of the **CeraPutty** allowed for a perfect bone healing and regeneration over the retrograde material.

References

- (1) Abusrewil, S.M., McLean, W. and Scott, J.A., 2018. The use of Bioceramics as root-end filling materials in periradicular surgery: A literature review. The Saudi dental journal, 30(4), pp.273-282.
- (2) Nasseh, A.A. and Brave, D., 2015. Apicoectomy: The Misunderstood Surgical Procedure. Dentistry Today, 34(2), pp.130-132. 



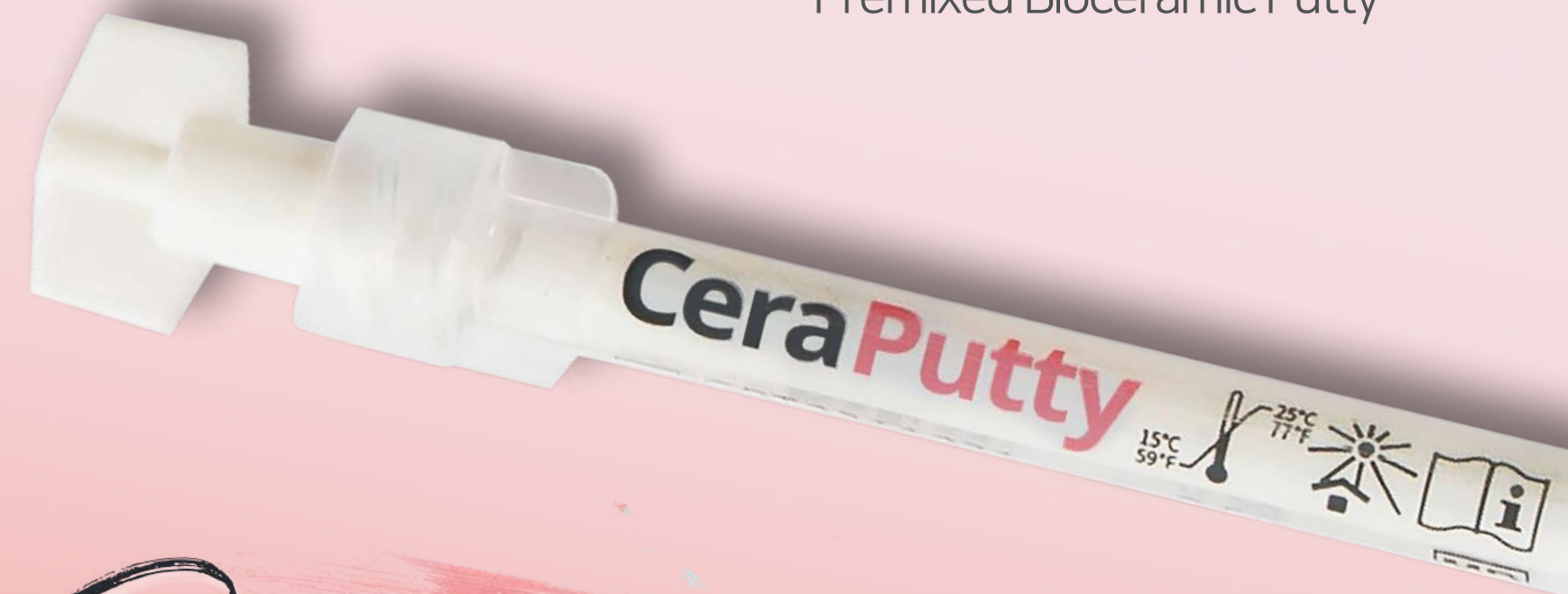CeraPutty brochure



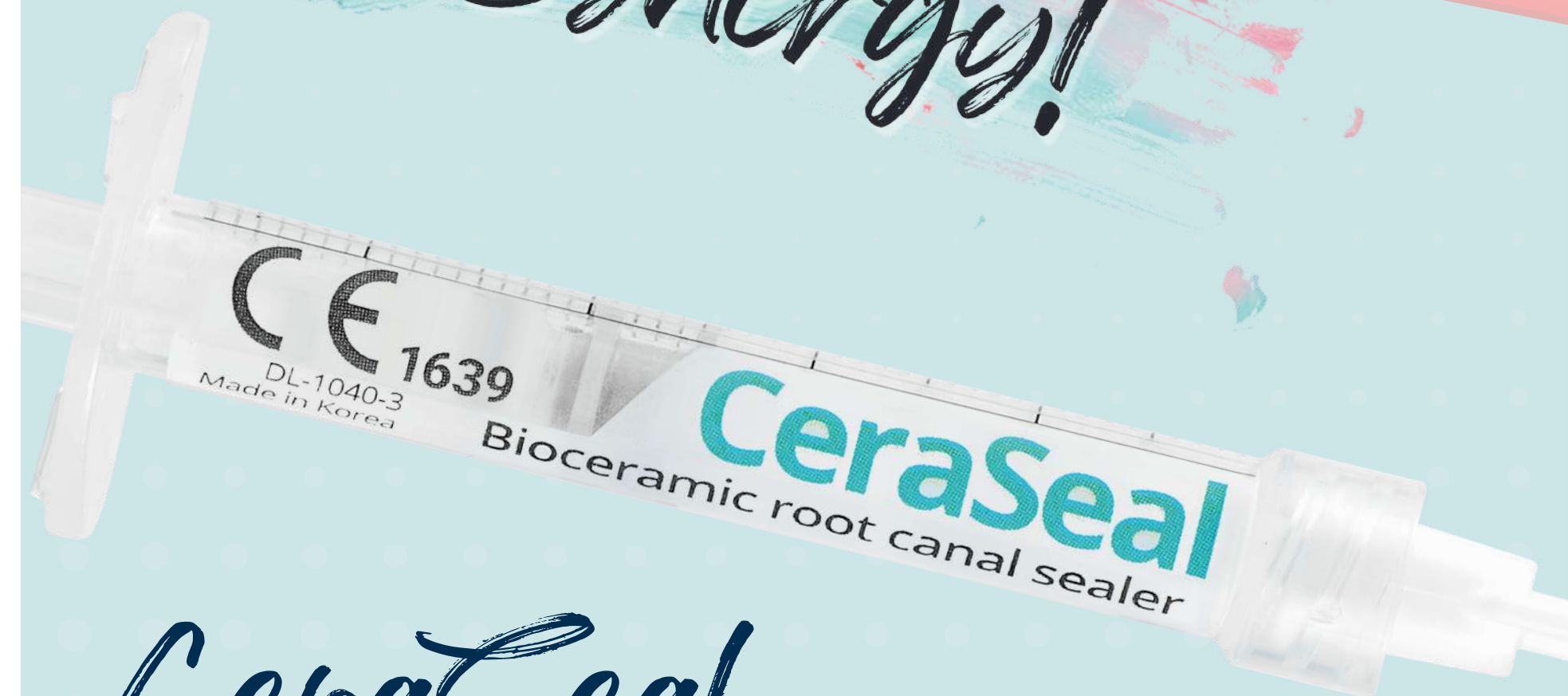CeraSeal brochure

CeraPutty

Premixed Bioceramic Putty



Real Bioceramic Synergy!

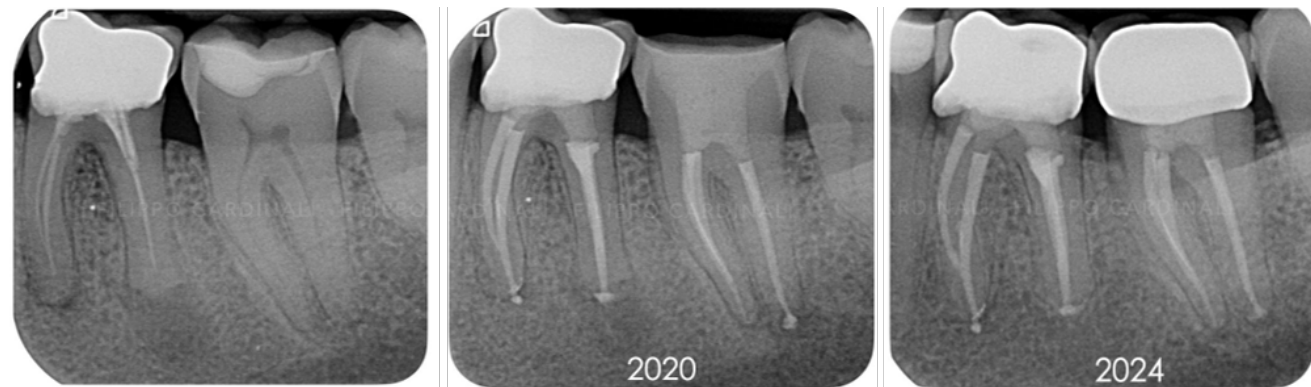


CeraSeal

Calcium Silicate-based Bioceramic Sealer

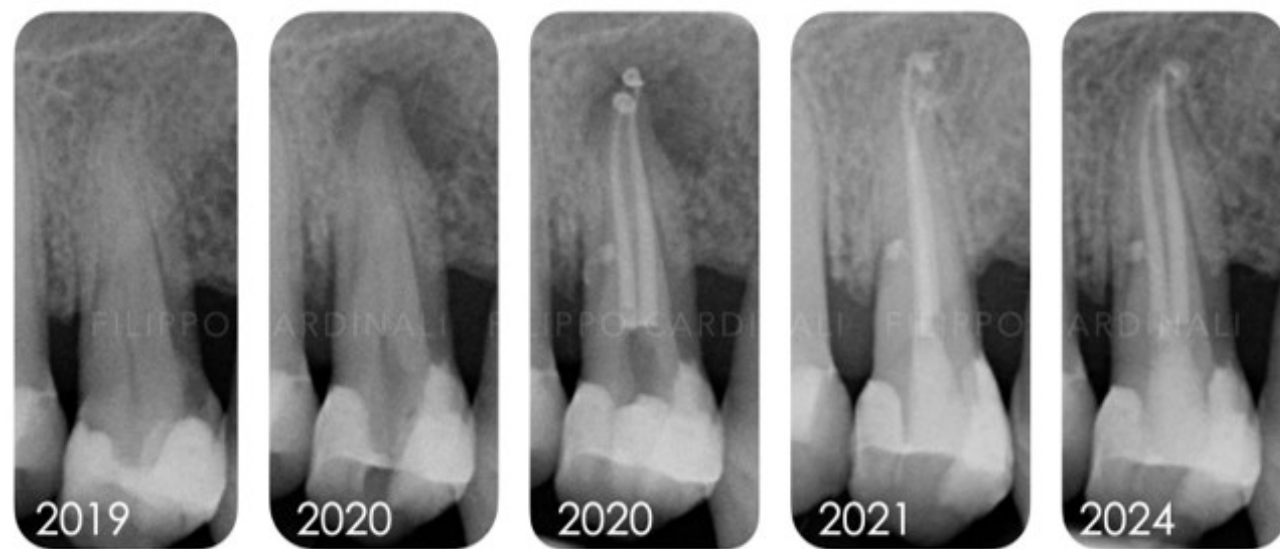CeraSeal Clinical Case

Courtesy of Dr. Filippo Cardinali



Retreatment 36 with lesion and Treatment of symptomatic 37 - 4 years follow-up.

Patient was referred for 2 problems: the tooth 36 was tender to percussion and palpation, the 37 presented the typical signs of "Cracked tooth Syndrome" with no probing and favorable prognosis. Treatments were done in 2 visits. During the first visit teeth were shaped, cleaned and dressed with calcium hydroxide. During the second visit the canals were obturated using the Cold Hydraulic Condensation Technique, a single cone with CeraSeal bioceramic sealer. Nice recall sent by the referral Dentist after 4 years. 📩

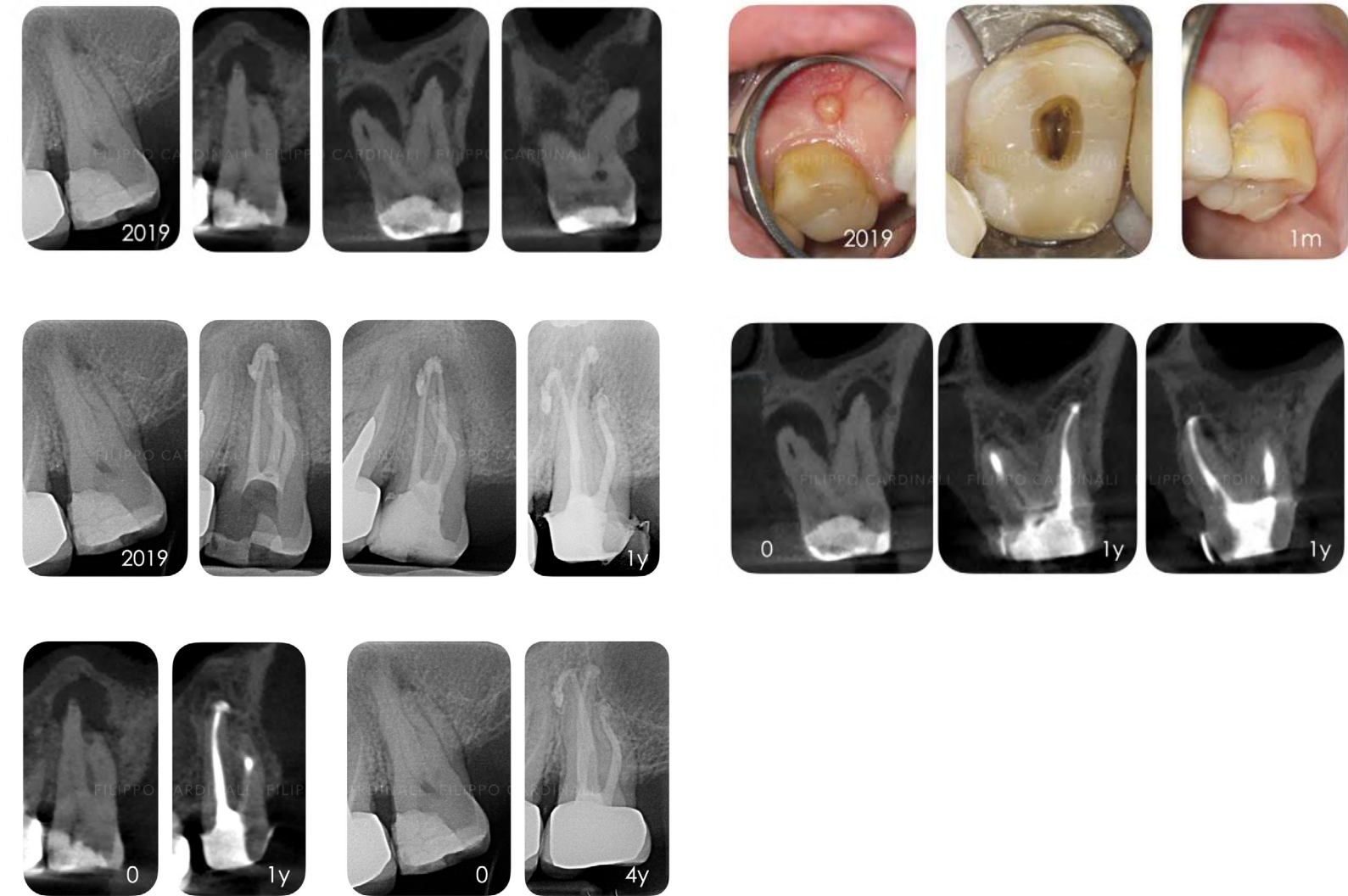


1.4: Failure of Indirect Pulp Capping - CHC & CeraSeal - 4 years recall Patient with periodontal disease was referred for the failure of indirect pulp capping on 1.4 done eight months before.

The patient came to my attention with complaints of pain and swelling in the right upper quadrant. Access cavity was made and pulp chamber was opened and pus was allowed to drain. After 2 days the tooth was shaped, cleaned and dressed with Calcium Hydroxide. After 2 weeks canals were obturated using the Cold Hydraulic Condensation Technique, single cone with CeraSeal bioceramic sealer. The hydraulic pressure created by the proper application of the technique resulted in the injection of a lateral canal. Review at 1 and 4 years shows the stability of this sealer based technique and the healing of the lesion. 📩

CeraSeal Clinical Case

Courtesy of Dr. Filippo Cardinali



2.7: Big Lesion - Sinus Tract - Overfilling - Healing - 4 years recall Patient was referred for the treatment of a symptomatic 2.7 with a big lesion and sinus tract.

After 4 weeks dressing with Calcium Hydroxide, the sinus tract healed, symptoms disappeared and the canals were obturated using the Cold Hydraulic Condensation Technique, a single cone with CeraSeal bioceramic sealer. At the post operative radiograph a big overfilling was present, not happy at all for that but it happens. The tooth was secured with a temporary crown and it was finalized with a Zirconia crown after the healing at 1 year was assessed with a CBCT. Nice recall sent by the referral Dentist after 4 years. 📩



Dr. Filippo Cardinali DDS (Italy)

Graduated summa cum laude in Dentistry in 1992. Active Member and Vice-President of the Italian Society of Endodontics. Certified Member of the European Society of Endodontology. Associate Member American Association of Endodontists. Gold Member of Style italiano Endodontics. Private practice, concentrating mainly in Endodontics and Restorative Dentistry, author of publications on journals of national and international sector, speaker at national and international congresses and workshops.

Instagram @cardinali_endodontics Facebook @filippo.cardinali.5

CERASEAL CLINICAL CASE REVIEW



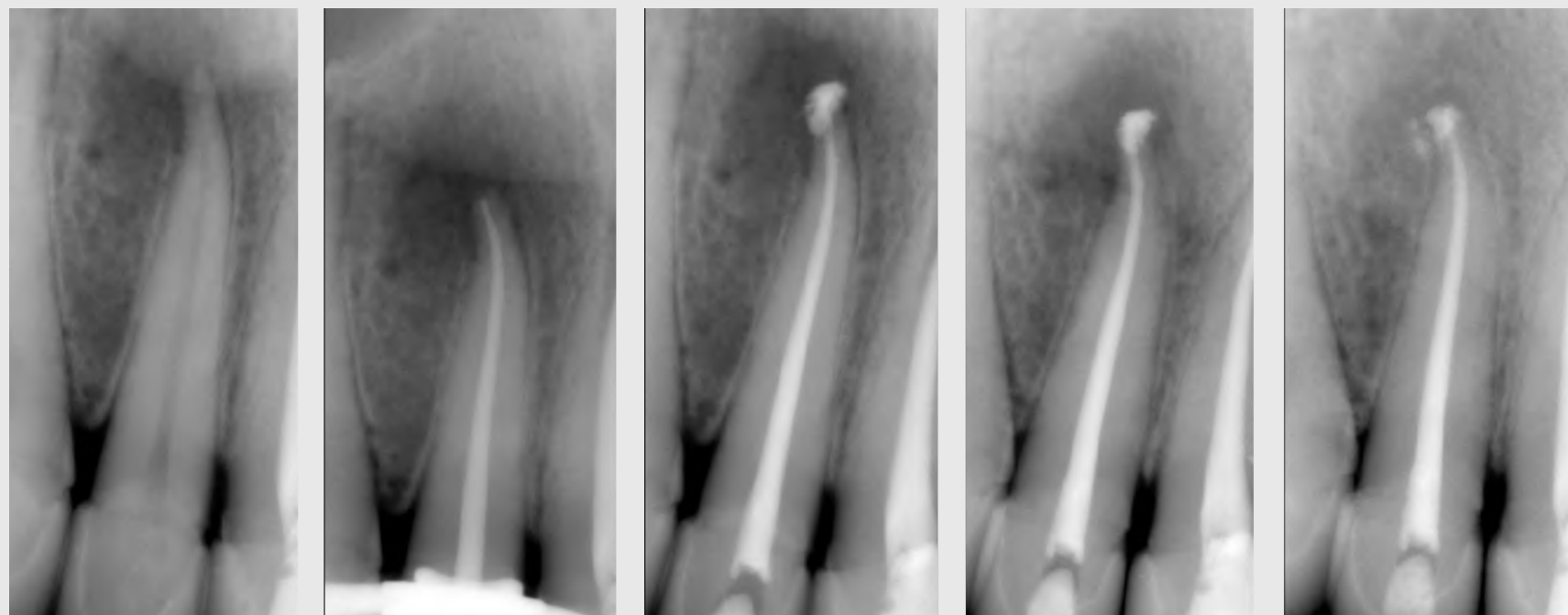
COURTESY OF
DR.MOSTAFA ANWAR BDS (EGYPT)

Graduated from Ain Shams University, Egypt. Diploma of Healthcare & Hospital Management from the American University in Cairo. Master Degree of Endodontics from Ain Shams University on June 2015 & PhD Researcher. International Dental Conferences & Endodontics Key Opinion Leader. Co-Author of Retreatments by SIE. Micro-Endodontics Specialist at private practice, Cairo and the Gulf area. Instagram @mostafa_anwar facebook @ Mostafa Anwar

CERASEAL
CLINICAL CASE
REVIEW

COURTESY OF DR.MOSTAFA ANWAR

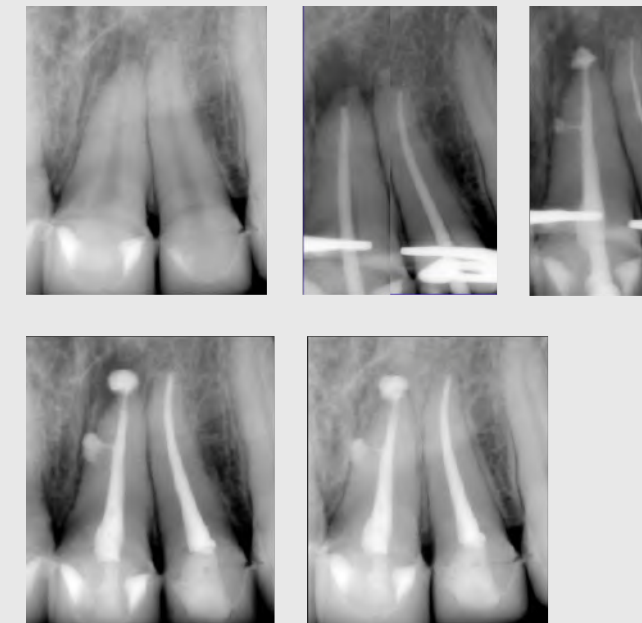
ROOT CANAL TREATMENT FOR UPPER LATERAL INCISOR



A Male patient was referred for RCT to his Upper Left Lateral Incisor.

This Lateral incisor had Symptomatic Apical Periodontitis with Moderate sized lesion as shown in the PA radiograph with previous crown restoration. Note the discontinuity of the lamina dura due to the infection. Single visit RCT was performed and proper disinfection protocol was followed, then Hydraulic Condensation Obturation Technique using "CeraSeal" Bioceramic Sealer. There was unintentional sealer puff periapically, however the biocompatibility & bioactivity of the material are of great help, allowing rapid healing progress. Follow up of the case after 5 months shows good healing, tissue repair, bone formation, intact lamina dura and most importantly; MATERIAL STABILITY & INTEGRITY over time. 📷

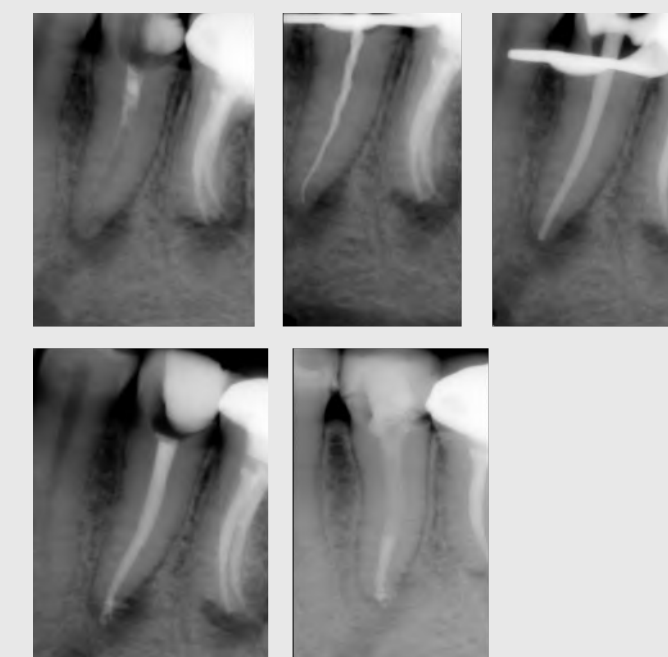RCT OF UPPER LEFT CENTRAL & LATERAL INCISORS



Lateral canals aren't evident sometimes in the preoperative radiographs, however if there is a lateral lesion then we should suspect a lateral canal.

In this case, a male patient came complaining of continuous pain related to Upper Left Central and Lateral Incisors, whom he recently restored with crowns. So, Access cavity was made through the newly made Crowns to preserve them. Paying attention and great care to Disinfection protocols while getting the benefit of CeraSeal Bioceramic sealer's flowability shows how can we fill those lateral canals simply and efficiently. Tissue healing and bone repair with CeraSeal Integrity and Stability over time, indicates the success of such cases. One year follow up with Excellent results. 📷

RCT OF LOWER LEFT SECOND PREMOLAR



Bioceramic Sealers have changed the Endodontic treatment greatly as we started to see shorter healing periods with good tissue repair.

In this case, we can see an evident large bone loss due to the periapical infection present. After root canal treatment while using CeraSeal in Single Cone Hydraulic Condensation technique, the case was referred to the prosthodontist. Surprisingly, the patient came for follow up after 10 weeks without prior notice due to personal circumstances. Follow up Xrays showed very nice healing in progress, evident start of bone formation and tissue repair in such short period of time. The periapical lesion decreased in size and bone formation following root anatomy started. Patient was advised to change the crown restoration and appointed for another follow up visit. 📷



Celebrates Its 34th Anniversary with the Slogan 'One Dream, One Team'



The year 2024 marks the 34th anniversary of Meta Biomed's founding, and the entire team was together to celebrate this significant milestone. The event featured food trucks with a variety of delicious dishes, a beer truck for a fun and relaxed atmosphere, and a beautiful music concert. This lively celebration allowed all employees to enjoy the moment and reflect on the journey that has brought Meta Biomed to where it is today. To commemorate the occasion, each employee received a baseball jacket with the slogan "One Dream, One Team," symbolizing our unity and shared vision. This gift represents our strong commitment to teamwork and innovation as we move forward. With 34 years of success as our foundation, Meta Biomed is just getting started. We look forward to continued growth and to overcoming new challenges together, aiming for an even brighter future. 📧

Meta Biomed Achieves the '50 Million USD Export Tower' Award

Meta Biomed has been honored with the '50 Million USD Export Tower' award for its contributions to exploring overseas markets and expanding exports. This award is given to companies that have contributed to boosting exports and creating jobs. Additionally, Meta Biomed's CEO, Ms. Joanne Oh, was awarded the Presidential Citation for her outstanding efforts in pioneering new markets and contributing to economic growth. Meta Biomed previously won the '30 Million USD Export Tower' award in 2016, followed by Chairman Mr. Tony Oh receiving the esteemed 'Order of Industrial Service Merit (Gold) (금탑산업훈장)' last year. And this year, the company has achieved another milestone by receiving the '50 Million USD Export Tower' award, marking its continuous growth. This year's achievement reflects Meta Biomed's commitment to innovation and excellence as we continue to grow globally and reach new milestones. We extend our heartfelt gratitude to our exceptional employees, valued customers, and partners. Your unwavering support and trust have been the driving force behind our success. Together, we look forward to reaching even greater heights in the years to come. Thank you for being a part of our journey! 📧



The Largest Annual Scientific Dental Conference and Exhibition in the World

ايدك
AEEDC
DUBAI

4-6 FEBRUARY 2025

Leading the Dental World into the Future

Hall 5A 10

AEEDC.COM REGISTER NOW

IDS[®]
2025

LEADING DENTAL BUSINESS SUMMIT
COLOGNE, 25. - 29.03.2025
41st International Dental Show

Visit us!
Hall 11.1, Stand B.080

META BIOMED

EASY MAINTAINENCE!

EQ-V Fill

EQ-V Pack

Chemical Resistant

Unique Structure of Filling System

Removable Battery

WANTED! New Idea & Clinical Case

We're All Ears for Your Big Ideas!

Share your brilliance with us and help shape FLOSSING by Meta Biomed! Your idea will be the next big thing in our upcoming editions.

Show your BEST Clinical Cases made by CeraSeal

It'd be lovely if we could share your BEST CeraSeal Cases with our tons of followers all around the world. Don't lock up the amazing cases you got in the drawer. Show it off!

For more inquiries: dental@meta-biomed.com

Stay connected with us!

Follow our SNS channels by scanning the QR code and be a part of our engaging conversations and exclusive updates.

SCAN HERE

Facebook, Instagram, YouTube icons

Flossing is a newsletter made by Meta Biomed (Dental) in 2023, which means taking out various information and delivering it to you, as if you were flossing teeth. [Click to subscribe for Free.](#)



2025

HAPPY NEW YEAR

META BIOMED